

Urgosorb™ dressing: management of acute and chronic wounds

Jenny Stevens, Donna Chaloner

The care and management of acute and chronic wounds form a large part of the community health professional's workload. Costs for wound care continue to rise as many new products and treatments become available (Gray et al, 2002). Many studies have been conducted that look at individual aspects of wound management and also studies that look at several aspects, such as cost, healing outcomes and quality-of-life issues (O'Brien et al, 2000; Bale et al, 2001; Lohmann et al, 2004). More recently, a study aiming to quantify the amount of tissue viability care in the community has been undertaken. It was identified that in a district-wide nursing caseload of 2005 patients, there were 1619 tissue viability interventions (Chaloner et al, 2004). These interventions included prevention and management of leg ulcers and pressure ulcers and the management of acute and other chronic wounds. This helps to demonstrate the high demand for wound care and supports the continued investment in both research and education to ensure patients receive the highest possible standard of care.

There has, over the past decade, been a large increase in the types of wound dressings available for use and it can be difficult choosing the most appropriate dressing for each type of wound. Responsibility for patient assessment and product selection is mainly undertaken by nurses and it is fundamental that care is based on individual patient assessment, clinical- and cost-effectiveness (Hampton, 1999). In an effort to rationalize product selection, many primary care trusts are now developing wound management formularies. Design and development of such aids for clinical practice include clinical audit of products, reviewing available evidence to aid selection, education, training and reducing clinical risk through promotion of best practice.

In this article, the authors provide information on how they locally audited one product's effectiveness to establish suitability for future formulary inclusion. This was a prospective 10-patient case study series evaluating the use of Urgosorb™ primary dressing.

The product

Urgosorb™ is a sterile dressing comprising calcium alginate fibres and hydrocolloid and is recommended for sloughy and granulating wounds with moderate to high levels of exudate. Alginates are natural polymers extracted from brown algae, and have been recognized for their healing and haemostatic properties as early as the 18th century (Oliver and Blaine, 1948). The clinical efficacy is based on the ability of the alginate to absorb and form a gel to create a warm, moist environment that is favourable to healing. There are two main

Abstract

This article illustrates the outcomes of a 10-patient prospective case study series. The aim of the study was to evaluate the use of Urgosorb™ in the management of acute and chronic wounds. (Urgosorb™ is a dressing comprising calcium alginate fibres and hydrocolloid, and is recommended for sloughy and granulating wounds with moderate to high levels of exudate.) Parameters assessed were the effectiveness of exudate management and integrity of surrounding tissue, ease of removal, patient comfort, effectiveness of odour control and observation for any adverse reactions. Data were collected over a period of 6 weeks with weekly evaluations. Healing was not included in the study objectives as it was recognized this would be difficult on a range of highly variable wounds. Although healing was not assessed, 50% of the wounds did heal during the study period. Dressing removal was considered easy in the majority of cases, and patients experienced none, or only mild discomfort. Levels of exudate were well managed and there were no reports of any adverse events.

Key words: Wounds ■ Dressings ■ Research and development

families of alginate fibre-based dressings that are currently being used in wound management. These are alginate-rich in mannuronic acid (M-type) and those with a high content of guluronic acid (G-type). Although both have the properties to absorb and gel they differ in their behaviour on exuding wounds (Williams, 1999).

Hydrocolloids are interactive dressings consisting of a hydrocolloid base made from cellulose, gelatins and pectins. When the hydrophilic particles come into contact with wound fluid they swell to form a gel which comes in direct contact with the wound bed (Dealey, 1994).

The Urgosorb™ concept is to combine these two families of alginates with hydrocolloid particles to further enhance their ability to absorb but maintain the gelling effect so the dressing can be removed in one piece.

Study aims and objectives

Aim

The aim was to conduct a prospective case series evaluation of 10 patients to evaluate the clinical- and cost-effectiveness of Urgosorb™ for the management of acute and chronic wounds.

Jenny Stevens is Research Nurse (Tissue Viability) and Donna Chaloner is Clinical Nurse Specialist (Tissue Viability), Walsall Research and Education Centre, Walsall Teaching Primary Care Trust, West Midlands

Accepted for publication: May 2005

Objectives

For the objectives, the following parameters were measured during the evaluation:

- Effectiveness of exudate management
- Ease of dressing removal
- Patient comfort during use and on removal
- Effectiveness of odour control
- Integrity of surrounding tissue
- Adverse reactions.

Methodology

Following local, ethical approval, 10 patients were recruited onto this non-comparative case series evaluation. Patients were recruited from district nursing caseloads from one primary care trust in the UK. The patients were only included in the study if they were able to provide written informed consent and met the study inclusion and exclusion criteria.

These inclusion criteria were as follows:

- Patients were aged 18 years or over
- Patients were presenting with an acute or chronic wound
- Wounds were exuding moderate to high levels of exudate.

Patients were excluded if they were unable to understand the purpose of the study or unable to give consent. They were also excluded if the wound required debridement of necrotic tissue, extended to the bone or tendon, or if the patient had any known allergies to any of the dressing components. Consenting patients who satisfied these inclusion and exclusion criteria were evaluated for 6 weeks or until healing, whichever occurred first. Patients were assessed using standardized documentation. At the initial inclusion visit, a comprehensive patient history was recorded and a clinical evaluation of the wound was undertaken. This included wound type, duration and location of wound, condition of wound bed, e.g. slough, granulation and level of maceration to the surrounding skin.

Evidence of any clinical infection, level of malodour and the patient's perception of the level of pain experienced from the wound were also assessed. Pain levels were assessed using a 1–5 pain scale with 1 indicating no pain and 5 indicating severe pain levels. A digital photographic image was taken of the wound and wound measurements were taken using a disposable tape measure.

A wound pad made up of viscose and polyester secured by a low adherent net and a retention bandage, if required, was used as the secondary dressing. The dressing was changed as many times as the exudate levels dictated, but the wound was evaluated only once a week for the purpose of the study.

The weekly assessment was primarily based on user satisfaction as the authors recognize the difficulty in assessing healing rates over a 6-week period. The patients were asked how comfortable they found the dressing and if they experienced any pain on removal. Odour levels were recorded, as were the levels of exudate. A visual assessment of the wound bed and the condition of the surrounding skin was recorded. Documentation was made of how easy it was to remove the dressing, whether any local adverse event was observed to the wound or surrounding skin and if the wound appeared infected. All wound dimensions were measured and digital photographs were taken.

Case studies

During this study, the properties of Urgosorb™ were assessed using 10 individual case studies. Although 10 patients were recruited, only nine fully completed the study. One patient was withdrawn as a result of sinus development to a pressure ulcer and required further investigations to establish cause.

Although positive outcomes were observed in all of the remaining nine patients, for the purpose of this article, three case studies are described in detail. However, a summary of all results demonstrating overall outcome measures are given in *Table 1*.

Patient	Type/location of wound	Wound duration	Wound size first assessment	Wound bed first assessment	Wound size at 6 Weeks	Wound bed at 6 Weeks
1	Pilonidal sinus	18 months	2.34 cm ²	50% granulation 50% slough	Healed on week 3	N/A
2	Amputation site: great toe	5 weeks	13.11 cm ²	70% granulation 30% slough	Healed	N/A
3	Ulcer to left foot	10 weeks	2.6 cm ²	40% slough 60% granulation	0.06 cm ²	95% granulation 5% slough
4	Incision and drainage: abscess on elbow	1 week	3 cm ²	60% slough 40% granulation	0.32 cm ²	20% slough 20% granulation 60% epithelialization
5	Pilonidal sinus	2 weeks	1.47 cm ²	100% granulation	Healed on week 3	N/A
6	Abdominal surgical	11 weeks	2.9 cm ²	100% granulation	Healed on week 4	N/A
7	Caesarean section site	15 weeks	0.7 cm ² 2 cm depth	95% granulation 5% slough	Healed on week 5	N/A
8	Arterial leg ulcer: right leg	6 months	2.47 cm ²	30% slough 70% granulation	1.65 cm ²	5% slough 95% granulation
9	Pressure ulcer: right heel – grade 3*	7 months	16 cm ²	100% green/black slough	16 cm ²	100% yellow slough
10	Withdrawn					

*Source: International Association for Enterostomal Therapy (1988)

Patient 1

Mr S was a 19-year-old man who had a history of a pilonidal abscess that had been incised and drained. The postoperative wound failed to heal and further exploratory surgical intervention was required. The wound again failed to heal and at the time of the evaluation had been present for 18 months. Previous treatments had included various alginates and a hydrofibre. He had no previous medical history that

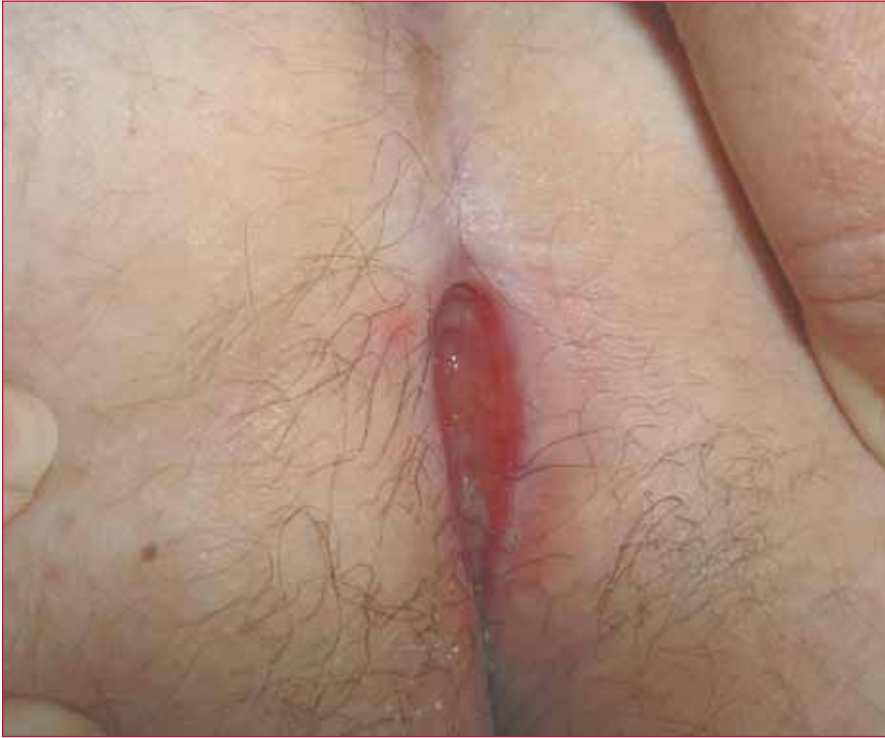

Figure 1. Patient 1: Initial postoperative wound resulting from incision and draining of a pilonidal abscess.

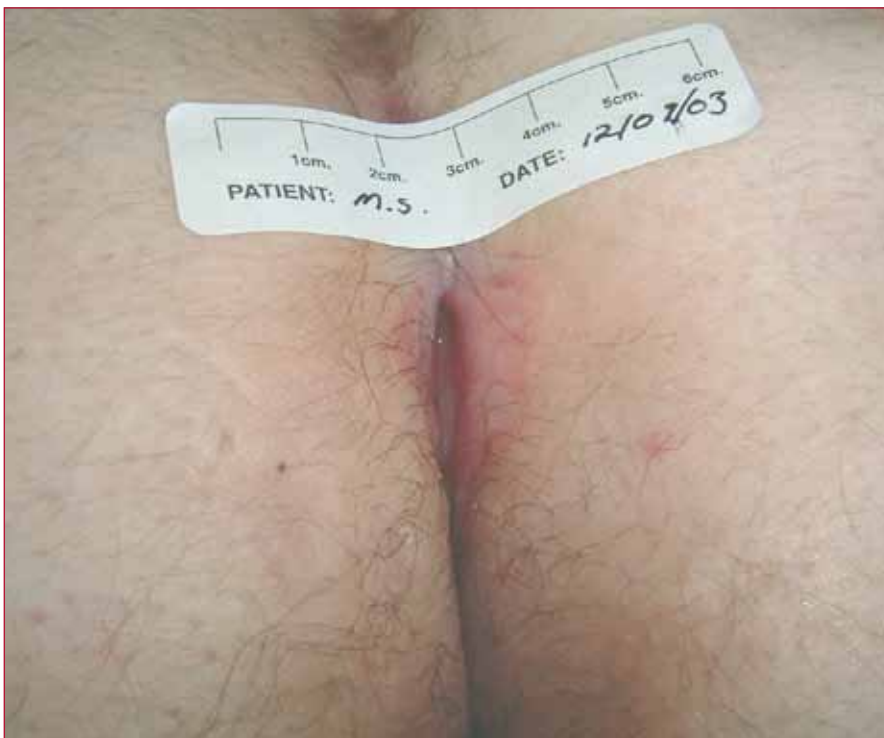

Figure 2. Patient 1: Wound after 14 days.

could have contributed to the wound failing to heal. Mr S agreed to have his treatment changed to Urgosorb™, dressed on a daily basis.

Initial assessment

The wound area measured 2.34 cm² with no depth (Figure 1). The wound bed was 50% slough and 50% granulation with moderate levels of exudate. He complained of no pain at dressing change or at other times and the wound was not producing any odour.

Week 1

After 7 days treatment with Urgosorb™ there was a significant improvement observed to the wound. The wound bed was 100% granulating and the area had decreased to 1.5 cm² with exudate levels remaining moderate. He complained of no pain or discomfort and the Urgosorb™ dressing was very easy to remove at every dressing change. The wound remained free from odour.

Week 2

After 14 days of treatment there was 95% epithelialization present leaving two small 'islands' of granulation measuring 6 mm² and 1 mm² respectively (Figure 2). Exudate levels were low and the wound remained free from odour.

Week 3

After 21 days treatment, full healing was achieved (Figure 3).

Patient 2

Mr A was a 69-year-old diabetic man who had been controlled on oral hypoglycaemics for 15 years. Owing to peripheral vascular disease, Mr A had an amputation of his left great toe 5 weeks previously resulting in a slow-to-heal postoperative wound. The wound had high levels of exudate causing maceration to the surrounding skin. Previous treatments had included alginates and a hydrofibre. Mr A agreed to have his treatment changed to Urgosorb™ and initially required daily dressings.

Initial assessment

The wound area measured 13.11 cm² with a depth of 1.5 cm (Figure 4). The wound bed was 70% slough and 30% granulation, there was no odour and no clinical signs of infection. Exudate levels were high and the surrounding skin had become macerated with erythema present. He complained of no pain or discomfort at dressing changes.

Week 1

Significant improvement was observed after 1 week of treatment with the wound area reducing in size to 11.16 cm² and a depth of 1 cm. The wound bed was 70% granulation and 30% slough. Exudate levels had reduced, resolving the maceration to the surrounding skin but erythema was still present. The wound remained free from odour.

Week 4

Following 28 days of treatment, the wound area had reduced to 2.5 cm² with no depth (Figure 5). The wound bed was 30%

Results

As outlined earlier, the primary outcomes of this study were based on user satisfaction rather than healing. However, on study completion 50% of the wounds had healed (*Figure 10*). *Table 1* demonstrates the healing and changes in wound bed appearance in more detail.

Of the nine patients that completed the study, six were suffering from chronic wound types and three were acute surgical wounds. For the purpose of this study, a chronic wound is defined as 'a wound caused by underlying causative factors or an acute surgical episode greater than 6 weeks in duration'. Duration of wounds for all nine patients ranged from 1 week to 18 months. The acute wounds duration ranged from 1–5 weeks and for chronic wounds, duration ranged from 10 weeks to 18 months. Patients' age ranged from 19–86 years. In this study, 60% of patients were male and 40% were female (*Table 2*).

Figures 11 and 12 illustrate the ease of dressing removal and pain experienced on dressing removal. In total, 93% (42/45) of dressing removals were easy or very easy. Only 6.6% (3/45) of dressing removals were difficult. This was a result of the dressing fibres adhering to the wound bed. There were 77% (35/45) experiencing no pain and 17% (8/45) experiencing only mild pain on dressing removal. Moderate pain was

granulation and 60% epithialization (*Figure 8*). Exudate levels had reduced so the dressing only required changing three times a week, as the surrounding skin was now healthy. Mrs H was pain free at all times. The wound remained free from odour and clinical signs of infection.

Week 6

The wound area had reduced to 0.06 cm² equating to 97.7% of the wound achieving healed status from the time of the initial assessment (*Figure 9*). The level of exudate was minimal, the wound was odourless and Mrs H remained pain free. The wound subsequently achieved full healing the following week.

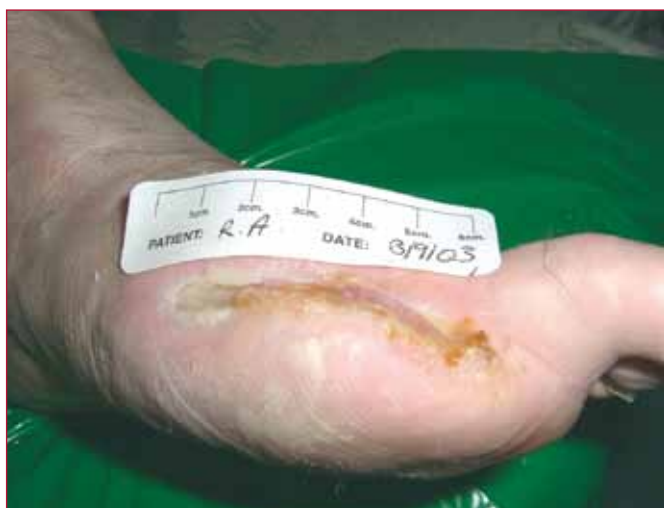

Figure 5. Patient 2: Wound after 28 days.

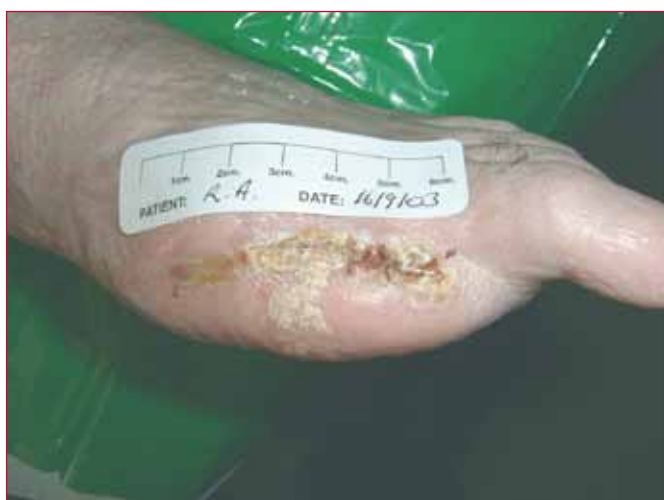

Figure 6. Patient 2: Wound after 6 weeks.

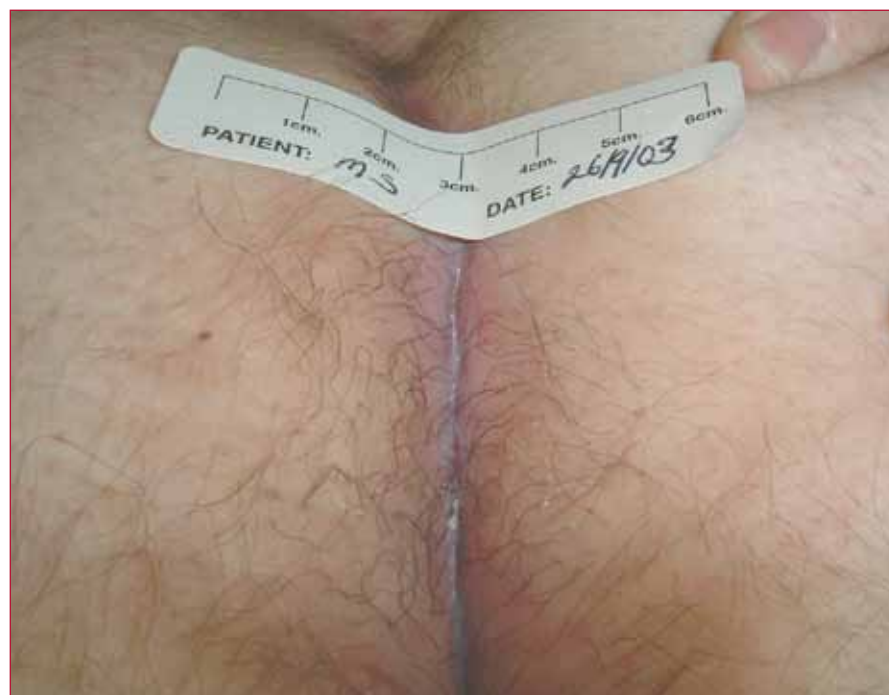


Figure 3. Patient 1: Wound after 21 days.

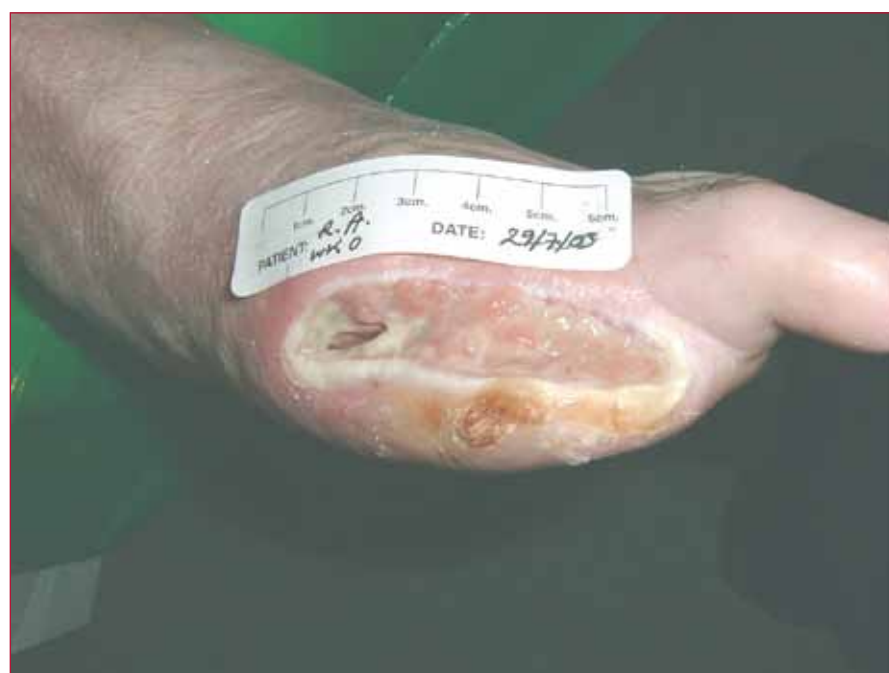

Figure 4. Patient 2: Initial postoperative wound — amputation of great toe.

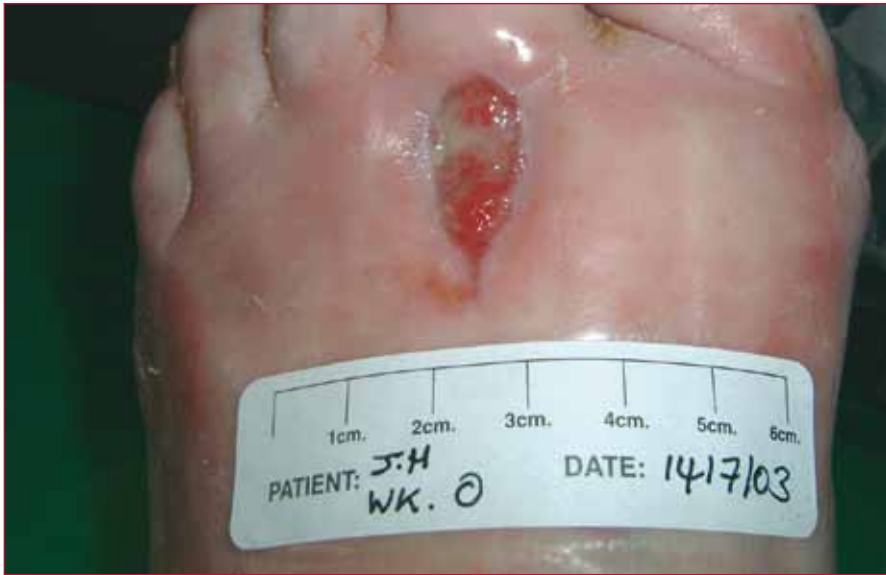

Figure 7. Patient 3: Initial ulcer on dorsum of left foot.

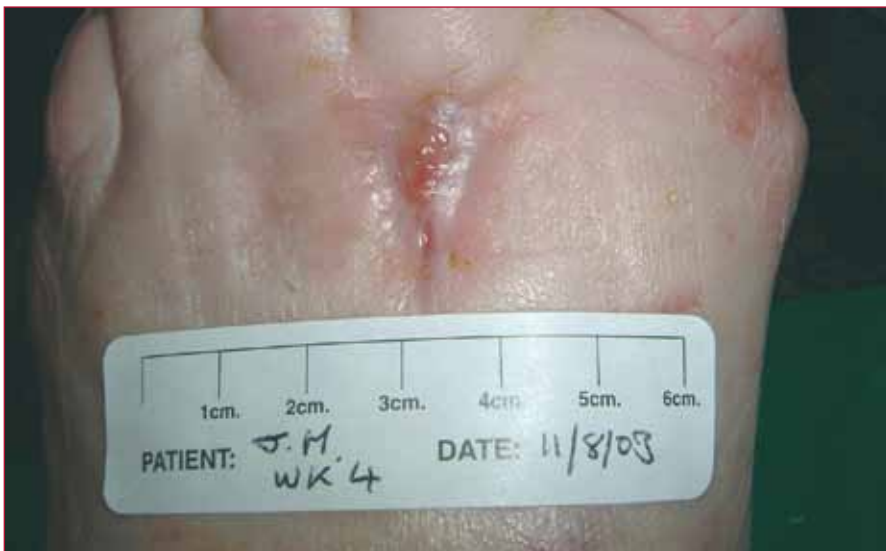

Figure 8. Patient 3: Foot ulcer by week 4.

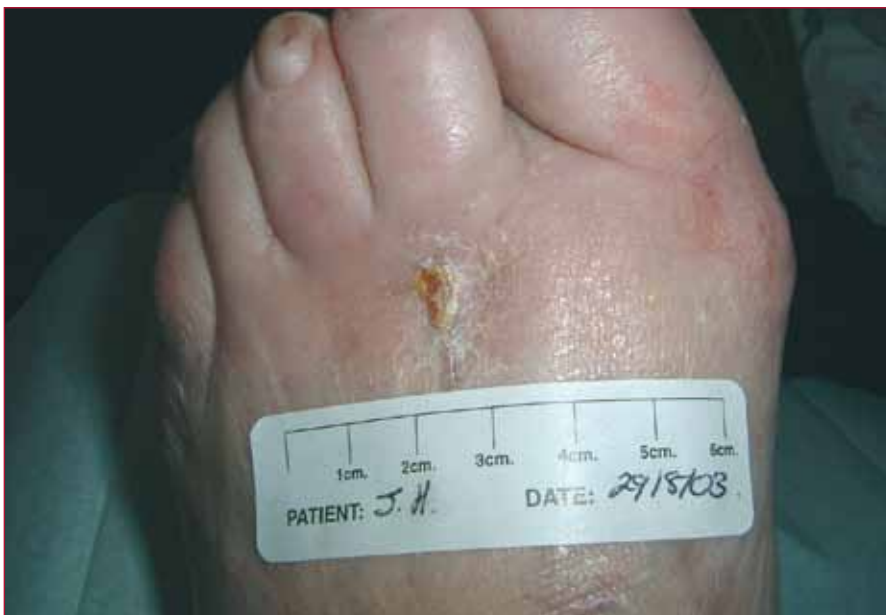

Figure 9. Patient 3: Foot ulcer by week 6.

slough, 50% granulation and 20% epithialization. Exudate levels were low and the interval of dressing changes had been reduced to twice weekly. The surrounding skin was healthy and Mr A complained of no pain or discomfort. The wound remained free from odour.

Week 6

The wound was healed with a superficial surface of dry tissue. with no exudate or erythema to the surrounding skin (Figure 6).

Patient 3

Mrs H was a 71-year-old woman who was an insulin-dependent diabetic. She had a history of osteoarthritis and hypertension. Mrs H developed an ulcer to the dorsum area of her left foot. She had suffered previous ulcers to this area, which had healed, but the present wound was of 10-weeks' duration with no observed improvement. She had no significant arterial disease. Previous treatments had included cadexomer iodine, hydrofibre and alginates.

Mrs H agreed for her treatment to be changed to Urgosorb™, dressed on a daily basis.

Initial assessment

The wound area measured 2.6 cm² and the wound bed was 60% granulation and 40% slough (Figure 7). Exudate levels were moderate causing maceration and erythema to the surrounding skin. There was no odour or clinical signs of infection. Mrs H complained of pain to the wound on dressing changes, which required analgesia.

Week 1

Significant improvement was seen to the wound's size as the area had reduced to 1.53 cm². The wound bed was 70% slough and 30% granulation. Exudate levels remained moderate and maceration remained to the surrounding skin. Although the dressing was difficult to remove at each dressing change, she did not suffer pain on removal and no longer required analgesia. The wound remained free from odour and clinical signs of infection.

Week 4

The wound area was 0.54 cm² and the wound bed 40%

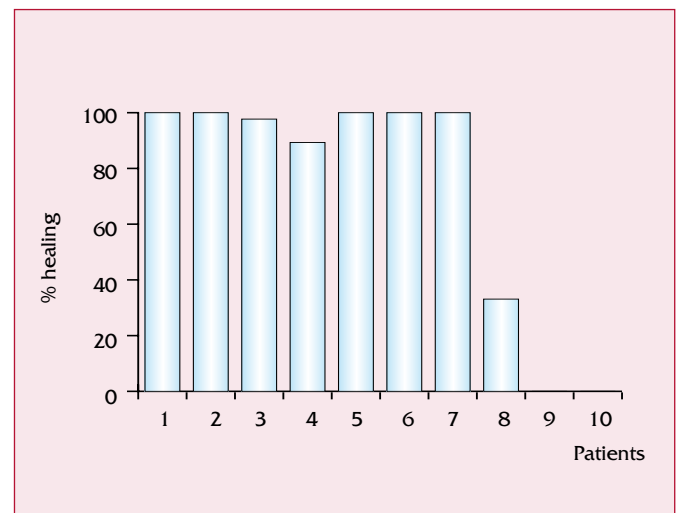


Figure 10. Healing percentages.

experienced in 4.4% (2/45) of cases.

Management of exudate was favourable with fluid being well absorbed, assisting in resolving maceration to the surrounding skin. When assessing odour levels, 66% (6/9) of patients experienced some wound malodour but this had resolved for each patient by the end of the assessment period. There were no reports of adverse reactions to the dressings.

Conclusion

Although it is recognized that the choice of topical dressing only forms a small part of the total care a patient suffering from an open wound requires, it is fundamental that the selection is both clinically- and cost-effective.

The authors acknowledge the limitations of this study, in that the sample size was small and it was a non-comparative study, therefore, how far the results can be generalized is restricted. However, it would appear from the results of this small study, that Urgosorb™ performs extremely well in wounds presenting with both sloughy and granulating tissue with moderate to high levels of exudate. This has been apparent in both chronic and acute wounds. BJN

Bale S, Baker N, Crook H, Rayman A, Rayman G, Harding KG (2001) Exploring the use of an alginate dressing for diabetic foot ulcers. *J wound care* **10**(3): 81–4

Chaloner D, Stevens J, Roberts S, Franks P (2004) *Quantifying Tissue Viability in the Community. Proceedings of Tissue Viability Conference*. Expertise in Wound Management, Torquay

Dealey C (1994) *The Care of Wounds*. Blackwell Science, London

Gray DC, Russell F, Flett A (2002) Mepore Ultra and Alldress: primary and secondary dressings. *Br J Nurs (Suppl)* **11**(20): S50–S4

International Association for Enterostomal Therapy (1988) IAET Scale. Dermal Wounds: Pressure Sores. *J Enterostomal Ther* **15**(1): 4–17

Hampton S (1999) Choosing the Right Dressing in Miller M, Glover D, eds. *Wound Management Theory and Practice*. Nursing Times Books, London: 116–29

Lohmann M, Thomsen JK, Edmonds ME, Harding KG, Apelqvist J, Gottrup F (2004) Safety and performance of a new non-adhesive foam dressing for the treatment of diabetic foot ulcers. *J wound care* **13**(3): 118–20

O'Brien JF, Grace PA, Burks PE (2000) Prevalence and aetiology of leg ulcers in Ireland. *Ir J Med Sci* **169**(2): 110–12

Oliver LC, Blaine G (1948) Haemostasis with absorbable alginates in neurosurgical practice. *Br J Surg* **147**: 307–10

Williams C (1999) Alginate and cavity dressings for the diabetic foot. *The Diabetic Foot* **2**(4): 139–40

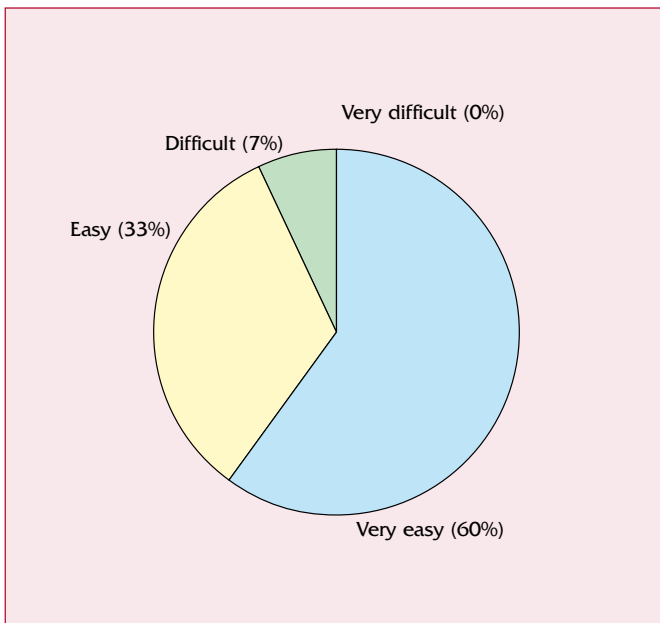


Figure 11. Ease of dressing removal (%).

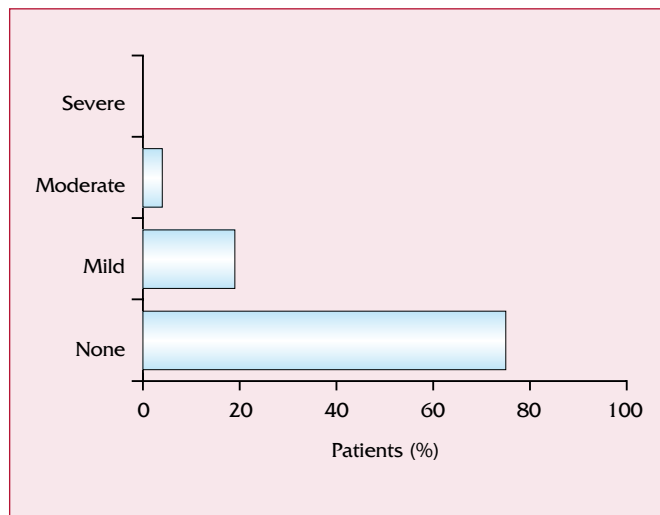


Figure 12. Pain felt on dressing removal (% of patients).

Patient	Gender	Age (years)
1	Male	19
2	Male	69
3	Female	71
4	Male	73
5	Male	24
6	Male	78
7	Female	41
8	Male	66
9	Female	86
10 (Withdrawn)	Female	74

KEY POINTS

- Management of both acute and chronic wounds account for a high proportion of community nurses' workload.
- Responsibility for product selection is mainly nurse led.
- Urgosorb™ comprises calcium alginate fibres and hydrocolloid.
- Case study data indicates Urgosorb™ is suitable for acute and chronic wounds.